

Initial Experience With a New Refractive Rotationally Asymmetric Multifocal Intraocular Lens

Jan A. Venter, MD; Dean Barclay, MD; Martina Pelouskova, MSc; Claire E. L. Bull, BSc

ABSTRACT

PURPOSE: To assess efficacy, safety, predictability, and patient satisfaction after refractive lens exchange with a new refractive rotational asymmetric multifocal intraocular lens.

METHODS: One hundred six eyes of 53 patients after bilateral refractive lens exchange with the SBL-3 lens (Lenstec, Inc., Christ Church, Barbados) implantation were evaluated. The mean preoperative refractive sphere was $+1.06 \pm 2.63$ diopters (D) (range: -8.25 to +5.00 D) and the mean refractive cylinder was -0.51 ± 0.46 D (range: -2.00 to 0.00 D). Monocular and binocular uncorrected and corrected distance visual acuity, uncorrected and distance-corrected intermediate visual acuity, uncorrected and distance-corrected near visual acuity, defocus curve, and patient satisfaction were evaluated 3 months postoperatively.

RESULTS: At 3 months, 84.9% (90 eyes) were within ± 0.50 D of emmetropia. The mean postoperative uncorrected distance visual acuity was -0.03 ± 0.09 logMAR (6/6 Snellen) monocularly and -0.08 ± 0.08 logMAR (6/4.8 Snellen) binocularly. The mean monocular and binocular uncorrected near visual acuity were 0.12 ± 0.12 and 0.08 ± 0.10 logMAR (6/7.5 Snellen), respectively. Defocus curve showed a slight drop off for vergences equivalent to intermediate vision. Although some night vision phenomena were reported, overall satisfaction was high. No intraoperative or postoperative complications occurred in this study.

CONCLUSIONS: The new refractive rotationally asymmetric intraocular lens provided good range of vision for near, intermediate, and distance. Long-term follow-ups are necessary to evaluate the performance of this intraocular lens.

[*J Refract Surg.* 2014;30(11):770-776.]

Replacing the presbyopic or cataractous crystalline lens with an artificial implant to yield the best possible visual outcomes and high patient satisfaction is the aim of modern lens-based surgery. Several multifocal technologies have been developed and evaluated for this purpose,^{1,2} and attempts to develop the lens design that can restore vision at all focal distances are ongoing.

Refractive rotationally asymmetric intraocular lenses (IOLs), introduced into clinical practice 5 years ago, have already been widely adopted by surgeons around the world. Their development brought a brand new concept to multifocal IOL technology. Instead of traditional concentric rings providing different foci, this lens has two sectors: a larger sector for distance vision, and an inferior surface-embedded sector for near vision with a smooth transition between them. In theory, having fewer transition zones from one power to the next should result in less light dispersion and improved contrast sensitivity. In rotationally asymmetric lenses, there is only one transition zone between the two segments, resulting in only 7% energy loss. Experience with the first commercially available lens of this type (Lentis Mplus; Oculentis GmbH, Berlin, Germany), its advantages, and shortcomings have already been discussed.³⁻¹⁶

In the current study, we report our initial experience with the second refractive rotationally asymmetric IOL on the market: the SBL-3 lens (Lenstec, Inc., Christ Church, Barbados). To our knowledge, this is the first study of this new lens design. Predictability, visual outcomes, and patient satisfaction were evaluated at 3 months postoperatively.

PATIENTS AND METHODS

This prospective consecutive case series study enrolled 53 patients who had refractive lens exchange to correct ametropia and presbyopia with bilateral implantation of the SBL-3 IOL.

From Eye and Laser institute, Port Elizabeth, South Africa.

Submitted: May 12, 2014; Accepted: September 2, 2014; Posted online: November 5, 2014

The authors have no financial or proprietary interest in the materials presented herein.

Correspondence: Jan A. Venter, MD, Eye and Laser Institute, 205 Cape Road, Newton Park, Port Elizabeth, South Africa. E-mail: drjanventer@gmail.com

doi:10.3928/1081597X-20141021-09

Inclusion criteria were age of 45 years or older, corrected distance visual acuity (CDVA) of 6/6 or better in each eye, ametropia combined with presbyopia, and corneal astigmatism less than 1.50 diopter (D). Exclusion criteria were a history of glaucoma or retinal detachment, corneal disease, corneal surgery, ocular inflammation, neuro-ophthalmic disease, and macular degeneration or retinopathy. Informed consent was obtained from all patients. The study adhered to the tenets of the Declaration of Helsinki and was approved by the local ethics committee.

PATIENT ASSESSMENT

All patients had a full preoperative ophthalmologic examination, including refraction, distance and near visual acuities, slit-lamp examination, tonometry, and dilated funduscopy. Additionally, corneal topography (OPD-Scan II; NIDEK Co., Ltd., Gamagori, Japan), endothelial cell count (SP 2000P specular microscope; Topcon Europe BV, Capelle aan den IJssel, The Netherlands), biometry (IOLMaster; Carl Zeiss Meditec, Jena, Germany), and retinal optical coherence tomography (Cirrus 4000 OCT; Carl Zeiss Meditec) were performed.

Postoperatively, patients were evaluated at 1 day, 1 week, and 1, 3, and 6 months. Visual acuities and the refractive status were measured at each follow-up. In addition, 3 months postoperative protocol included the following measurements: manifest refraction, uncorrected distance visual acuity, CDVA, uncorrected and distance-corrected intermediate visual acuity at 70 cm, uncorrected and distance-corrected near visual acuity at 40 cm, defocus curve, and patient satisfaction.

Distance visual acuity was evaluated with Snellen charts. Intermediate and near visual acuities were evaluated with the logarithmic near Early Treatment Diabetic Retinopathy Study chart. The defocus curve was obtained monocularly and binocularly with the patient's best distance refractive correction while viewing a distance chart under photopic conditions. The negative lenses were added in 0.50-D steps and the visual acuity was recorded for each type of blur. The same procedure was repeated using positive lenses. Letter sequences were randomized between each level of defocus. Defocus acuities were first corrected for spectacle magnification and monocular and binocular defocus curves were constructed for vergence distances ranging between -4.00 and +1.00 D in 0.50-D steps.

A patient satisfaction questionnaire was administered at the 3-month follow-up visit. This questionnaire was purpose-developed to evaluate visual symptoms, satisfaction with visual acuity while performing various distance and near tasks, and overall satisfaction with surgery results (Table 1). Patients were asked to rate the incidence of visual phenomena

TABLE 1

Patient Satisfaction Questionnaire at 3 Months Postoperatively

Question	Percent
How satisfied are you with the outcome of your procedure?	
Very Satisfied	75.5%
Satisfied	18.9%
Neither	5.7%
Dissatisfied	0.0%
Very dissatisfied	0.0%
How much difficulty do you have performing tasks that require good close up vision (such as cooking, fixing things around the house, sewing, using hand tools, and reading or working with a computer?)	
No difficulty at all	69.8%
A little difficulty	17.0%
Moderate difficulty	11.3%
A lot of difficulty	1.9%
Would you recommend this procedure to your family/friends?	
Yes	98.1%
No	1.9%
Night vision phenomena (rated on scale from 1 [no difficulty] to 7 [severe difficulty])	Mean ± SD
How much difficulty do you have with your vision at night because of starburst around bright lights?	2.8 ± 1.5
How much difficulty do you have with your vision at night because of glare from bright light?	3.0 ± 1.6
How much difficulty do you have with your vision at night because of halo from bright light?	3.2 ± 1.6
How much difficulty do you have with your vision due to double vision or ghosting around images?	2.5 ± 1.6

SD = standard deviation

such as starburst, halo, glare, and ghost images/double vision on a scale between 1 (no difficulty) and 7 (severe difficulty).

SBL-3 IOL

The SBL-3 (Figure A, available in the online version of this article) is a bi-aspheric asymmetrical refractive multifocal IOL, which has a +3.00-D addition in the inferior anterior optic. This translates to approximately +2.50 D at the spectacle plane. It has a small wedge-shaped transition zone separating the (superior) distance from the near power zone. The percentage of optic that is occupied by the near segment is 42%. The IOL length is 11.0 mm, with an optic size of 5.75 mm and it is manufactured from a hydrophilic acrylic material. The multifocal IOL has a neutral aberration profile,

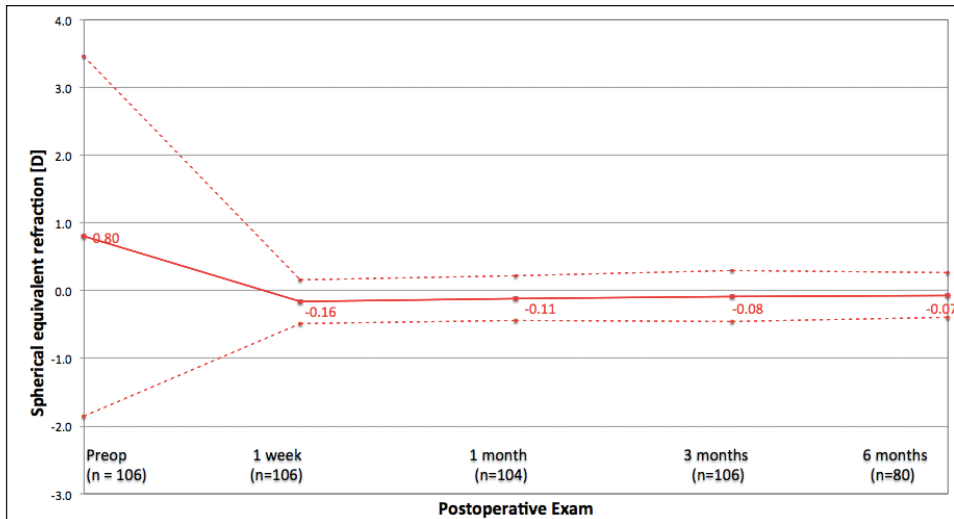


Figure 1. Stability of spherical equivalent for a period of 6 months. D = diopters

allowing remnant corneal spherical aberration to impart some additional depth of focus. The diopter range is between +10.0 and +36.0 D with 0.50 increments, with the most commonly used mid powers (range: +15.0 to +25.0) being available in 0.25-D increments. The shape of the haptic is similar to the accommodating lens of the same manufacturer (Tetraflex; Lenstec, Inc.), however, it is three times wider and 1.5 times thicker. Compared to Tetraflex, the SBL-3 lens is not designed for axial movement of the optics to achieve accommodation.

SURGICAL TECHNIQUE

All surgeries were performed by two experienced surgeons (JAV, DB). The pupil was dilated with one pellet of Mydrasert (Spectrum Thea Pharmaceuticals, Cheshire, United Kingdom). The surgery was performed under sub-Tenon anesthetic block. After phacoemulsification, the foldable IOL was inserted in the capsular bag through a 2.75-mm corneal incision using the manufacturer’s injector (Model LC1620I; Lenstec, Inc.). The IOL was positioned with the near sector opposite to the quadrant where the decentered visual axis was detected related to the pupil. All incisions were placed on the steepest corneal meridian, which was pre-marked with the patient in the upright position to prevent cyclotorsion. The nondominant eye was treated first, followed by the dominant eye 1 week later. Lens calculation was performed using the Holladay II formula.

Postoperatively, patients were instructed to instill one drop of levofloxacin 0.5% (Oftaquix; Santen Pharmaceutical, Munich, Germany) four times daily for 2 weeks, one drop of dexamethasone 0.1% (Maxidex, Alcon Laboratories, Fort Worth, TX) four times daily for 2 weeks, and one drop of ketorolac trometamol 0.5% (Acular, Allergan, Irvine, CA) four times daily for 1 month.

STATISTICAL ANALYSIS

Visual acuity measurements were converted to logMAR notation for statistical analysis. Normality of sample size was tested with the Kolmogorov–Smirnov test. The Student’s paired *t* test was used to compare preoperative and postoperative data where normality of dataset was assumed; otherwise, the Wilcoxon rank-sum test was applied. Summary statistics, such as means and standard deviations, were presented to describe the study population. All data were analyzed using Microsoft Office Excel 2007 (Microsoft Corp., Redmond, WA) and the STATISTICA (StatSoft, Inc., Tulsa, OK) program. A *P* value of less than .05 was considered statistically significant.

RESULTS

One hundred six eyes of 53 patients were included in the study (21 males, 32 females). The mean age of the study cohort was 58.2 ± 6.3 years (range: 48 to 71 years). The mean spherical power of the implanted IOL was 21.16 ± 3.14 D (range: 12.00 to 25.50 D) and the mean preoperative mesopic pupil size was 5.3 ± 0.8 mm (range: 3.0 to 6.7 mm). Twenty eyes were myopic and 86 eyes were hyperopic prior to surgery.

Figure 1 displays refractive stability of manifest spherical equivalent for a period of 6 months. Because no statistically significant difference was found between spherical equivalent at 3 and 6 months, all remaining graphs were plotted for 3-month data where thorough examination was performed.

The mean preoperative refractive sphere was +1.06 ± 2.63 D (range: -8.25 to +5.00 D) and changed to +0.11 ± 0.36 D, ranging from -0.75 to +1.00, (*P* < .01, Wilcoxon rank-sum test). The mean refractive cylinder reduced from -0.51 ± 0.46 D (range: -2.00 to 0.00 D) to -0.39 ± 0.37 D (range: -1.75 to 0.00 D). This change

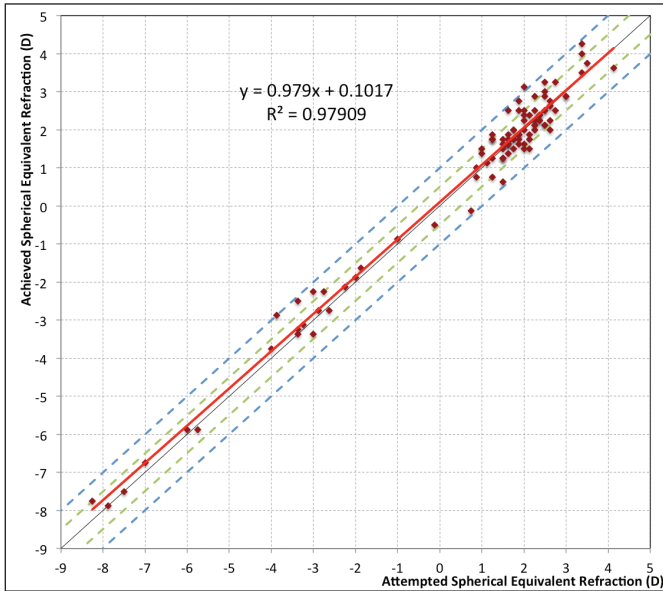


Figure 2. Attempted versus achieved spherical equivalent. The area between the green dashed lines represents spherical equivalent within ± 0.50 diopters (D) and the area between the blue dashed lines contains spherical equivalent between ± 1.00 D of emmetropia. The red solid line is the linear regression.

was statistically significant ($P = .03$, Wilcoxon rank-sum test). **Figure 2** plots the predictability of spherical equivalent. Of 106 eyes, 64.2% (68 eyes) were within ± 0.25 D, 84.9% (90 eyes) were within ± 0.50 D, and 99.1% (105 eyes) were within ± 1.00 D of emmetropia.

Table 2 summarizes the mean logMAR values for postoperative near, intermediate, and distance visual acuity. The percentage of patients achieving uncorrected distance visual acuity of 6/6 (0.0 logMAR) or better was 87.7% (93 eyes) monocularly and 94.3% (100 eyes) binocularly. Of 106 eyes, 87.7% (93 eyes) achieved monocular uncorrected near visual acuity and 98.1% (104 eyes) of patients achieved binocular uncorrected near visual acuity of 6/9 (approximately J3) or better. The percentage of patients achieving monocular and binocular uncorrected intermediate visual acuity 6/9 or better was 80.2% (85 eyes) and 90.6% (96 eyes), respectively. **Figure 3** displays the cumulative binocular uncorrected distance, intermediate, and near visual acuities. The mean CDVA changed from -0.06 ± 0.07 logMAR (6/4.8 Snellen) preoperatively to -0.07 ± 0.06 logMAR (6/4.8 Snellen) postoperatively, which was not statistically significant ($P = .26$, paired t test). Safety (change between preoperative and postoperative CDVA) is plotted in **Figure 4**.

Figure 5 shows the mean monocular and binocular defocus curve. Monocular curve shows a peak of -2.50 D defocus (equivalent to 40 cm viewing distance from the eye) and at 0.0 D (equivalent to distance vision)

TABLE 2

Mean 3-Month Postoperative Visual Acuities

Parameter	Mean \pm SD (logMAR) (Range)
UNVA (40 cm)	
Monocular	0.12 \pm 0.12 (-0.1 \pm 0.5)
Binocular	0.08 \pm 0.10 (-0.1 to 0.3)
DCNVA (40 cm)	
Monocular	0.11 \pm 0.10 (-0.1 to 0.3)
Binocular	0.08 \pm 0.09 (-0.1 to 0.3)
UIVA (70 cm)	
Monocular	0.16 \pm 0.11 (0.0 to 0.4)
Binocular	0.13 \pm 0.10 (-0.1 to 0.4)
DCIVA (70 cm)	
Monocular	0.15 \pm 0.10 (-0.06 to 0.4)
Binocular	0.10 \pm 0.09 (-0.1 to 0.3)
UDVA	
Monocular	-0.03 \pm 0.09 (-0.2 to 0.3)
Binocular	-0.08 \pm 0.08 (-0.2 to 0.18)
CDVA	
Monocular	-0.07 \pm 0.06 (-0.2 to 0.08)
Binocular	-0.10 \pm 0.06 (-0.2 to 0.08)

SD = standard deviation; UNVA = uncorrected near visual acuity; DCNVA = distance-corrected near visual acuity; UIVA = uncorrected intermediate visual acuity; DCIVA = distance-corrected intermediate visual acuity; UDVA = uncorrected distance visual acuity; CDVA = corrected distance visual acuity

with a slight drop off for intermediate distances (defocus: -1.50 for 67 cm and -1.0 for 100 cm). This drop off is much less obvious on the binocular defocus curve.

Table 1 summarizes the results of the patient satisfaction questionnaire at 3 months postoperatively and mean scores for night vision disturbances.

No intraoperative or postoperative complications occurred in this study.

DISCUSSION

Attempts to combat presbyopia with multifocal IOL implants led to a development of different intraocular lens technologies. These can be divided into a few main categories: refractive, diffractive, and those combining both principles.^{1,2} Diffractive lenses are based on the principle of diffraction, whereby light changes direction when it encounters an obstacle (diffractive zones across the lens surface). The light is then directed into different focal points, for near and distant objects. On the other hand, refractive multifocal IOLs have different powers integrated into refractive zones. They can either be traditional, rotationally symmetric with circular refractive zones, or rotationally asymmetric with

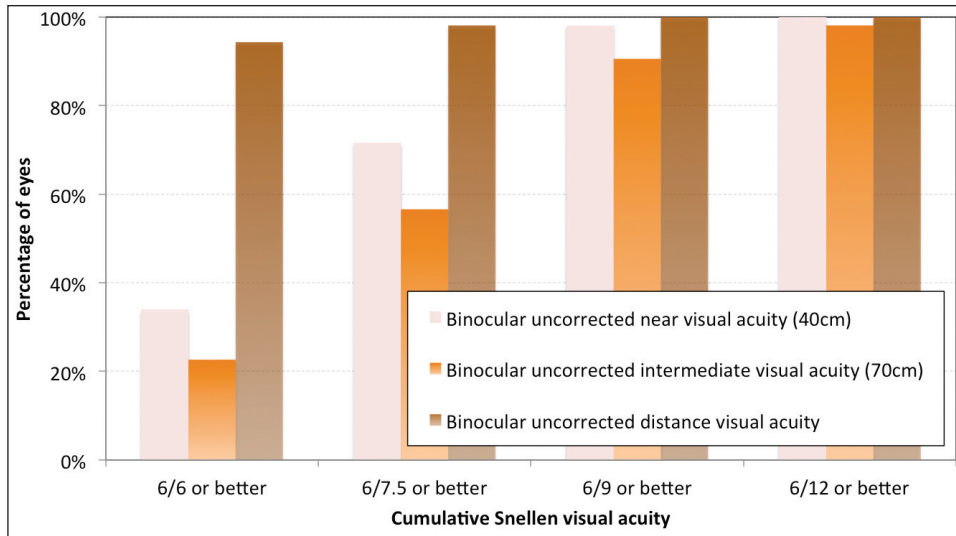


Figure 3. Cumulative binocular uncorrected distance, intermediate, and near visual acuity.

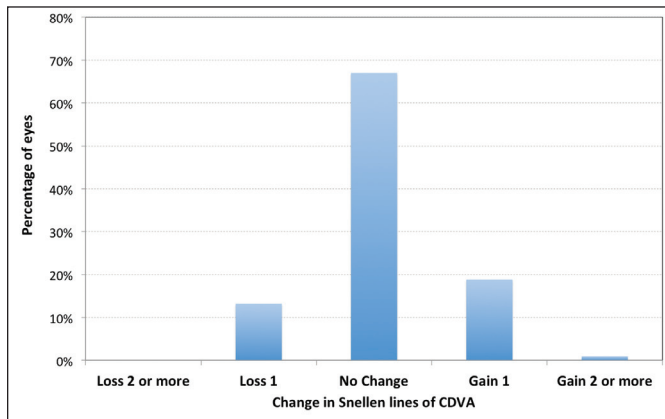


Figure 4. Safety comparison of preoperative and postoperative corrected distance visual acuity (CDVA).

inferior near section. The first commercially available rotationally asymmetric design (Lentis Mplus; Oculentis GmbH, Berlin) has already been extensively evaluated.³⁻¹⁶ The SBL-3 lens is based on the same principle of two refractive segments (near and distance), but the near segment extends closer to the peripheral optic, whereas the near sector in the Lentis Mplus is significantly regressed from the peripheral optic. Extended near segment could potentially result in fewer night vision optical disturbances and improved near vision.

A crucial role in the performance of any multifocal IOL is its predictability of refractive outcome. The new SBL-3 lens is manufactured in quarter diopter increments and ± 0.11 D tolerance in the most commonly used dioptric range. Of 106 eyes analyzed in this study, 95 required a lens from this premium range (15.0 to 25.0 D). A recent large population study on predictability of cataract surgery¹⁷ found 40%, 75%, and 95% within ± 0.25 , ± 0.50 , and ± 1.00 D, respectively, even with the use of optimized A-constants. Our results

are superior to this, with 64.2% eyes within ± 0.25 D, 84.9% eyes within ± 0.50 D, and 99.1% eyes within ± 1.00 D of emmetropia. Providing these are our initial cases, refractive predictability could be improved further with the use of optimized A-constant. Refractive stability would, however, need to be evaluated over a long period of time. Studies of the previous design of rotationally asymmetric lenses also highlighted the importance of a haptic design to support the lens in the capsular bag, which provides better stability and predictability and avoids IOL tilt that can negatively affect the performance of this rotationally asymmetric design.¹⁶ This was previously addressed with the use of capsular tension rings and the introduction of a plate haptic design instead of a C-loop.^{12,13,15} Although we did not see any cases of refractive shift or IOL tilt in our cohort, long-term follow-up is necessary to assess this.

The mean near visual acuity in this study was 0.12 ± 0.12 logMAR (6/7.5 Snellen) monocularly and 0.08 ± 0.10 logMAR (6/7.5 Snellen) binocularly. Unaided near vision reported with previous design of refractive rotationally asymmetric lens (Lentis Mplus) ranged between 0.08 and 0.30 logMAR (6/7.5 and 6/12 Snellen).³⁻¹³ The mean unaided near visual acuity reported in the literature for diffractive lenses is 0.082 logMAR (6/7.5 Snellen) (95% confidence interval: 0.067 to 0.098), for refractive lenses 0.217 logMAR (6/9 Snellen) (95% confidence interval: 0.118 to 0.317), and 0.064 logMAR (6/7.5 Snellen) (95% confidence interval: 0.046 to 0.082) for the most commonly used hybrid diffractive-refractive lens (ReSTOR; Alcon Laboratories, Inc., Fort Worth, TX).¹ We achieved excellent uncorrected distance visual acuity (-0.03 ± 0.09 logMAR [6/6 Snellen] monocularly and -0.08 ± 0.08 logMAR [6/4.8 Snellen] binocularly). This could be attributed to the refractive predictability of the lens, but also to

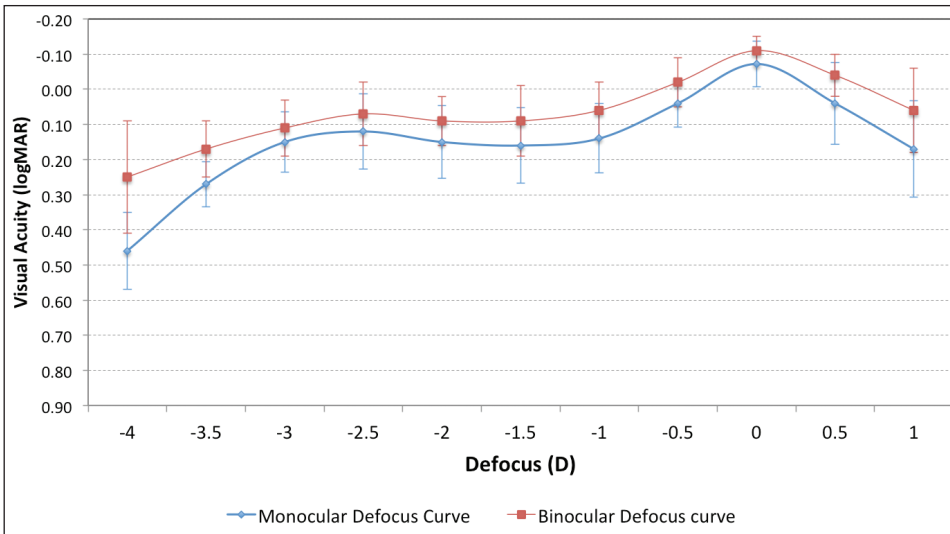


Figure 5. Mean monocular and binocular defocus curve. Error bars represent standard deviation for each defocus level. D = diopters

the fact that the mean preoperative CDVA in this study group was -0.06 ± 0.07 logMAR (6/4.8 Snellen) and a good visual rehabilitation for both distance and near vision was expected.

One of the greatest problems multifocal technology endeavors to overcome is the simultaneous achievement of good near and intermediate visual acuity. Generally, lenses with strong near addition have poor performance for intermediation vision, and lowering the near add to help intermediate distances results in poorer near vision.¹⁸⁻²⁰ Mixing and matching two lens technologies was known as one of the options to overcome this problem.^{21,22} Interestingly, previous studies found a good range for intermediate vision with the Lentis Mplus refractive rotationally asymmetric lens.^{4,5,8-11,13,15} Authors attribute this to either the gradual transition zone between the two areas of the IOL or some induction of primary coma with this design, providing a larger depth of focus.^{4,9,11,15} To address the issue of providing good vision at all distances, a new trifocal technology emerged in recent years (FineVision IOL; PhysiOL, Liege, Belgium). The trifocal design is based on the idea of combining two diffractive profiles, one for distance and near and one for distance and intermediate.²³ Published literature on this design found a good range of intermediate and near visual acuity on defocus curves, with only a slight drop off for intermediate distances.^{24,25} Defocus curve with the SBL-3 lens shows a similar profile to those reported with trifocal lenses. However, we achieved higher logMAR values for visual acuity at each level of defocus. Whether this is attributable to our sample characteristics (clear lens extraction patients with good preoperative CDVA compared to cataractous patients used in other studies) or to the SBL-3 lens providing clearer visual acuity at all distances compared to the diffractive design needs to be investigated in prospective comparative studies.

One of the most important factors resulting in patient dissatisfaction with multifocal technology is the overall reduced quality of vision, loss of contrast sensitivity, and night vision phenomena. The incidence of visual phenomena rated on a scale from 0 to 7 in our study was: starburst 2.8 ± 1.5 , glare 3.0 ± 1.6 , halos 3.2 ± 1.6 , and double vision/ghost images 2.5 ± 1.6 . Three months postoperative results are reported and neuroadaptation might still play a role in diminishing these symptoms. Despite some night vision phenomena, overall satisfaction with outcomes was high. In the design of the SBL-3 lens, loss of light in the transition between near and distance sector is negligible, and the lower the loss of energy with an IOL, the better contrast sensitivity and overall clarity of vision is expected. A limitation of our study is the absence of data on contrast sensitivity, which should be evaluated in future prospective studies and compared to a control group using a different IOL.

Good visual outcomes were achieved in our initial results of a new refractive rotationally asymmetric lens. The SBL-3 lens provided a good range of functional vision and no major complications were noted over a short follow-up period. A longer follow-up period is necessary to evaluate stability of this lens design.

AUTHOR CONTRIBUTIONS

Study concept and design (JAV, DB); data collection (MP, CELB); analysis and interpretation of data (JAV, DB, MP); drafting of the manuscript (JAV, MP, CELB); critical revision of the manuscript (JAV, DB); statistical expertise (MP, CELB); administrative, technical, or material support (MP, CELB); supervision (JAV, DB)

REFERENCES

1. Cochener B, Lafuma A, Khoshnood B, Courouve L, Berdeaux G. Comparison of outcomes with multifocal intraocular lenses: a meta-analysis. *Clin Ophthalmol*. 2011;5:45-56.

2. de Vries NE, Nuijts RM. Multifocal intraocular lenses in cataract surgery: literature review of benefits and side effects. *J Cataract Refract Surg.* 2013;39:268-278.
3. Muñoz G, Albarrán-Diego C, Javaloy J, Sakla HF, Cerviño A. Combining zonal refractive and diffractive aspheric multifocal intraocular lenses. *J Refract Surg.* 2012;28:174-181.
4. Alió JL, Plaza-Puche AB, Piñero DP, Javaloy J, Ayala MJ. Comparative analysis of the clinical outcomes with 2 multifocal intraocular lens models with rotational asymmetry. *J Cataract Refract Surg.* 2011;37:1605-1614.
5. Alió JL, Plaza-Puche AB, Javaloy J, Ayala MJ, Moreno LJ, Piñero DP. Comparison of a new refractive multifocal intraocular lens with an inferior segmental near add and a diffractive multifocal intraocular lens. *Ophthalmology.* 2012;119:555-563.
6. van der Linden JW, van Velthoven M, van der Meulen I, Nieuwendaal C, Mourits M, Lapid-Gortzak R. Comparison of a new-generation sectorial addition multifocal intraocular lens and a diffractive apodized multifocal intraocular lens. *J Cataract Refract Surg.* 2012;38:68-73.
7. Alió JL, Plaza-Puche AB, Javaloy J, Ayala MJ. Comparison of the visual and intraocular optical performance of a refractive multifocal IOL with rotational asymmetry and an apodized diffractive multifocal IOL. *J Refract Surg.* 2012;28:100-105.
8. Rosa AM, Loureiro Silva MF, Lobo C, et al. Comparison of visual function after bilateral implantation of inferior sector-shaped near-addition and diffractive-refractive multifocal IOLs. *J Cataract Refract Surg.* 2013;39:1653-1659.
9. Ramón ML, Piñero DP, Pérez-Cambrodí RJ. Correlation of visual performance with quality of life and intraocular aberrometric profile in patients implanted with rotationally asymmetric multifocal IOLs. *J Refract Surg.* 2012;28:93-99.
10. Muñoz G, Albarrán-Diego C, Ferrer-Blasco T, Sakla HF, García-Lázaro S. Visual function after bilateral implantation of a new zonal refractive aspheric multifocal intraocular lens. *J Cataract Refract Surg.* 2011;37:2043-2052.
11. Alió JL, Piñero DP, Plaza-Puche AB, Chan MJ. Visual outcomes and optical performance of a monofocal intraocular lens and a new-generation multifocal intraocular lens. *J Cataract Refract Surg.* 2011;37:241-250.
12. Venter JA, Pelouskova M, Collins BM, Schallhorn SC, Hannan SJ. Visual outcomes and patient satisfaction in 9366 eyes using a refractive segmented multifocal intraocular lens. *J Cataract Refract Surg.* 2013;39:1477-1484.
13. Alió JL, Plaza-Puche AB, Piñero DP. Rotationally asymmetric multifocal IOL implantation with and without capsular tension ring: refractive and visual outcomes and intraocular optical performance. *J Refract Surg.* 2012;28:253-258.
14. McAlinden C, Moore JE. Multifocal intraocular lens with a surface-embedded near section: short-term clinical outcomes. *J Cataract Refract Surg.* 2011;37:441-445.
15. Alió JL, Plaza-Puche AB, Javaloy J, Ayala MJ, Vega-Estrada A. Clinical and optical intraocular performance of rotationally asymmetric multifocal IOL plate-haptic design versus C-loop haptic design. *J Refract Surg.* 2013;29:252-259.
16. Montés-Micó R, López-Gil N, Pérez-Vives C, Bonaque S, Ferrer-Blasco T. In vitro optical performance of nonrotational symmetric and refractive-diffractive aspheric multifocal intraocular lenses: impact of tilt and decentration. *J Cataract Refract Surg.* 2012;38:1657-1663.
17. Aristodemou P, Knox Cartwright NE, Sparrow JM, Johnston RL. Formula choice: Hoffer Q, Holladay 1, or SRK/T and refractive outcomes in 8108 eyes after cataract surgery with biometry by partial coherence interferometry. *J Cataract Refract Surg.* 2011;37:63-71.
18. Buckhurst PJ, Wolffsohn JS, Naroo SA, et al. Multifocal intraocular lens differentiation using defocus curves. *Invest Ophthalmol Vis Sci.* 2012;53:3920-3926.
19. Petermeier K, Messias A, Gekeler F, Szurman P. Effect of +3.00 diopter and +4.00 diopter additions in multifocal intraocular lenses on defocus profiles, patient satisfaction, and contrast sensitivity. *J Cataract Refract Surg.* 2011;37:720-726.
20. Alfonso JF, Fernández-Vega L, Puchades C, Montés-Micó R. Intermediate visual function with different multifocal intraocular lens models. *J Cataract Refract Surg.* 2010;36:733-739.
21. Lubiński W, Podboraczyńska-Jodko K, Gronkowska-Serafin J, Karczewicz D. Visual outcomes three and six months after implantation of diffractive and refractive multifocal IOL combinations. *Klin Oczna.* 2011;113:209-215.
22. Yoon SY, Song IS, Kim JY, Kim MJ, Tchah H. Bilateral mix-and-match versus unilateral multifocal intraocular lens implantation: long-term comparison. *J Cataract Refract Surg.* 2013;39:1682-1690.
23. Gatinel D, Pagnouille C, Houbrechts Y, Gobin L. Design and qualification of a diffractive trifocal optical profile for intraocular lenses. *J Cataract Refract Surg.* 2011;37:2060-2067.
24. Sheppard AL, Shah S, Bhatt U, Bhogal G, Wolffsohn JS. Visual outcomes and subjective experience after bilateral implantation of a new diffractive trifocal intraocular lens. *J Cataract Refract Surg.* 2013;39:343-349.
25. Alió JL, Montalbán R, Peña-García P, Soria FA, Vega-Estrada A. Visual outcomes of a trifocal aspheric diffractive intraocular lens with microincision cataract surgery. *J Refract Surg.* 2013;29:756-761.



Figure A. The SBL-3 multifocal intraocular lens (Lenstec, Inc., Christ Church, Barbados).